

See discussions, stats, and author profiles for this publication at: <https://www.researchgate.net/publication/332548675>

Microcardia associated with Traumatic Reticulo Pericarditis (TRP) in an adult female ayrshire cow: A case report

Article · January 2019

CITATIONS

0

READS

261

6 authors, including:



Kipyego Serem

University of Nairobi

4 PUBLICATIONS 0 CITATIONS

[SEE PROFILE](#)



Tequiero Okumu Abuom

University of Nairobi

15 PUBLICATIONS 26 CITATIONS

[SEE PROFILE](#)



Daniel Gakuya

University of Nairobi

37 PUBLICATIONS 581 CITATIONS

[SEE PROFILE](#)



Gilbert Kirui

University of Nairobi

9 PUBLICATIONS 9 CITATIONS

[SEE PROFILE](#)

Some of the authors of this publication are also working on these related projects:



Soft Tissue Surgery [View project](#)



Enhancing dairy cattle productivity and livelihoods of smallholder dairy farmers in Kenya. [View project](#)



Case Report

Microcardia Associated with Traumatic Reticulo Pericarditis (TRP) In an Adult Female Ayrshire Cow: A Case Report

EK Serem^{1*}, TO Abuom¹, SG Peter¹, DW Gakuya¹, GK Kirui¹ and PG Mbuthia²

¹Department of Clinical Studies, University of Nairobi, P.O. Box 29053 00625, Nairobi, Kenya

²Department of Veterinary Pathology, Microbiology and Parasitology, University of Nairobi, P.O. Box 29053 00625, Nairobi, Kenya

*Corresponding author: kipyegoserem@yahoo.com; kipyegoserem04@gmail.com

Article History: Received: January 16, 2019 Revised: February 07, 2019 Accepted: February 10, 2019

ABSTRACT

A 7 months pregnant Ayrshire cow raised in open fields in Dandora area, Nairobi was presented to the Large Animal Clinic, University of Nairobi, on 6/11/2017 with a history of being off feed for a week and constipated. She had been treated for two weeks with Magnesium Sulphate oral drench and gentamycin injection without significant improvement. A week later, she deteriorated becoming completely anorexic and developed brisket oedema. General exam revealed good body condition, dullness and depression, predominant abdominal breathing, brisket oedema, careful gait, pronounced elbow abduction, distended jugular vein, grunting and teeth grinding. On physical examination the respiratory rate was 24 breathes per minute with a strong character, pulse rate of 92 beats per minute, temperature of 40.70 degrees Celsius, splashing heart sound, suppressed thoracic respiration and harsh lung sounds. Haematological analysis showed anaemia, evident by decreased haematocrit, haemoglobin concentration and red blood cell count. Leucocytosis, neutrophilia and lymphopaenia was also evident. A tentative diagnosis of terminal traumatic reticulo-pericarditis was made carrying a grave prognosis. Euthanasia was indicated but the cow died in the night of 8/11/2017. Post mortem revealed hydro-peritoneum, hydro-thorax, three (3) wires piercing through the reticula wall and diaphragm to the pericardial sac, fibrinous adhesions of reticulum, diaphragm and pericardium. The heart was atrophied with the pericardial sac holding 12 litres of creamy liquefied content with fibrin attachments. This report documents atrophied heart associated traumatic reticulo-pericarditis caused by several wires penetrating through the diaphragm in a cow raised in peri-urban area. In conclusion, the cow was from an urban farm and farming in such areas is more likely to predispose cattle to TRP due to uncontrolled grazing in urban centred which exposes them to unsafe foraging areas and fodder.

Key words: Traumatic Reticulopericarditis (TRP), Dairy farming, Microcardia

INTRODUCTION

Foreign body syndrome is a common disorder globally in large ruminants' especially dairy cattle reared around industrial areas (Parad *et al.*, 2017). It often has fatal outcome which leads to loss of premium genetic resources in farms. The etiology of TRP is ingestion of metallic materials via feed materials especially hay and free grazing cattle near construction sites (Cramer *et al.*, 2005). It's common among dairy animal reared in urban and peri-urban areas (Parad *et al.*, 2017). The prevalence of TRP in adult dairy cattle is has been attributed to management practices and lack of discriminatory dietary habits of the cattle.

Lack of adequate space and urbanization, animals are let outside for grazing, making them vulnerable to ingest the waste materials (Parad *et al.*, 2017). However, lack of mineral supplementation results in deficiencies thus, the cattle tend to consume materials containing metal resulting in traumatic reticulo-pericarditis disease (Diver and Peek, 2008).

The advancement of the modern diagnostic methods and treatment approach of foreign body syndrome cases has led to successful management of early reported cases (Braun *et al.*, 2018), however, most cases are presented to veterinary experts for treatment once the case as advanced and little can be done to manage the cases (Parad *et al.*, 2017). A case of terminal traumatic reticulo-pericarditis accompanied with micro-cardia is discussed.

Cite This Article as: Serem EK, TO Abuom, SG Peter, DW Gakuya, GK Kirui and PG Mbuthia, 2019. Microcardia associated with Traumatic Reticulo Pericarditis (TRP) in an adult female ayrshire cow: a case report. Inter J Vet Sci, 8(2): 73-78. www.ijvets.com (©2019 IJVS. All rights reserved)

Case history

An adult 7 months pregnant Ayrshire cow case number AD/033/2017 from Dandora, Embakasi North Sub-County - Nairobi, was presented to the Large Animal Clinic University of Nairobi on 6th November, 2017. The animal had developed bloat and constipation and lost appetite in the past previous week. Subsequently, she was treated with 1 kg of Magnesium Sulfate (Epsom salt®) administered per os and 20 mls of gentamicin injection given intramuscular route. There was slight relief of the bloat and slight improvement in her appetite. A week later, she became completely anorexic and developed brisket edema, prompting the owner to seek medical attention from the University of Nairobi, Large Animal Veterinary Clinic.

Clinical examination

General examination revealed fairly good body condition of about 3.5 in a scale of 5, dull and depression, flared nostrils, predominant abdominal breathing, brisket and submandibular edema, careful gait carrying, pronounced abduction of elbow, extended head and neck, distended jugular vein and, grunting and teeth grinding (Fig. 1 and Fig. 2). Physical examination revealed respiratory rate of 24 breathes per minute, pulse rate of 92 beats per minute, temperature of 40.7°C, grunting of tracheal auscultation, coughing, Ventral Oedema, splashing heart sound, suppress thoracic respiration and harsh lung sounds.

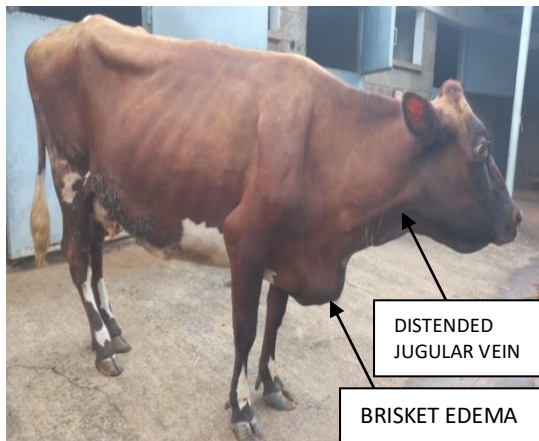

Fig. 1: The animal standing looking anxious, with a distended jugular vein, and brisket edema.

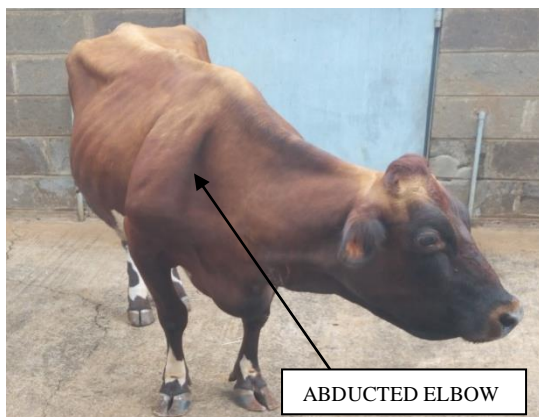

Fig. 2: The same cow showing abducted elbow and scapular and depressed (arrow).

Table 1: Hematology results of an EDTA blood sample of the adult Ayrshire cow

Parameter	Results	Normal Ranges
Hematocrit	21.2%	24.0-46.0%
Hemoglobin	6.7 g/Dl	8.0-15.0 g/dL
Red blood cell	$4.79 \times 10^6 \mu\text{L}$	5.0-10.0
Platelets	$181 \times 10^3 \mu\text{L}$	100.0-800.0
Mean corpuscular volume (MCV)	44.3fl	40.0-60.0
Mean corpuscular hemoglobin (MCH)	14.0 pg	11.0-17.0
Mean corpuscular hemoglobin concentration (MCHC)	31.6 g/Dl	30.0-36.0
White blood cells	$25.1 \times 10^3 \mu\text{L}$	4.0-12.0
Neutrophils	89%	15-33
Lymphocytes	11%	45.0-75.0

Hematological analysis

EDTA blood sample was collected from the tail vein for hematological examination. Table 1 below show the results. There was anaemia, evident by decreased hematocrit, hemoglobin Concentration and red blood cell count (highlighted in green). The leucocytes were elevated with a significantly high neutrophil count (highlighted in blue) but with a lymphopenia.

Case management

A tentative diagnosis of traumatic reticulo-pericarditis was made following the history, clinical examination and hematological results. Due to the severity of presentation and the reported history prognosis was expected to be grave and the owner was advised. On animal welfare account euthanasia was indicated but she died on the night of 8/11/2017. The carcass was submitted for full post mortem at the Department of Veterinary Pathology, Microbiology and Parasitology, University of Nairobi.

Post-mortem finding

Musculoskeletal system

The carcass was in fair nutritional status; however, congestion was observed. Subcutaneous edema was observed on various parts of the body including the neck regions, brisket and ventral thoracic region (Fig. 3).

Gastrointestinal system

Fluid accumulation was observed in abdominal cavity (hydro-peritoneum) and thoracic cavity (hydrothorax) (Fig 4), spleen was atrophic, liver was swollen, degenerated and had a hydatid cyst, rumen impacted with dry feed containing foreign material like ropes, plastic wires and polythene bags (Fig. 5). The reticulum was relatively empty with adhesions of the reticular wall to the diaphragm. The serosal surface also had fibrinous deposition. Examination of reticular contents revealed presence of ten, five and one shilling coins, 8 nails, 5 copper wires and 2 sewing needles (Fig. 6). Some of the nails were lying horizontally, while others together with a couple of wires, pierced through the reticular wall into the peritoneal and pericardial spaces.

Thoracic cavity

Pericardium was adhered to diaphragm with wires and nails protruding from the exposed surfaces (Fig. 6), the heart, pericardium was enlarged with creamy liquefied pus approximately 12 liters with fibrin attachments (Fig. 7 and 8), atrophy of the heart, lungs had atelectasis of apical and cardiac lobes and there was an extensive fibrinous reaction on the lung surface.



Fig. 3: The carcass present observed subcutaneous Edema (arrow).

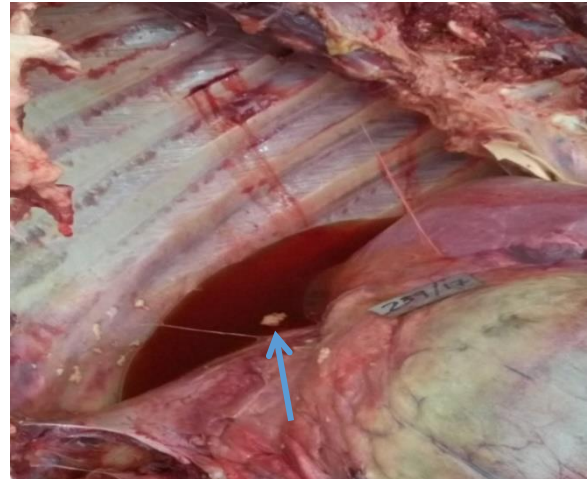


Fig. 4: Fluid accumulation within the thoracic cavity (arrow).



Fig. 5: Dry ruminal content with a plastic bag (red arrow).

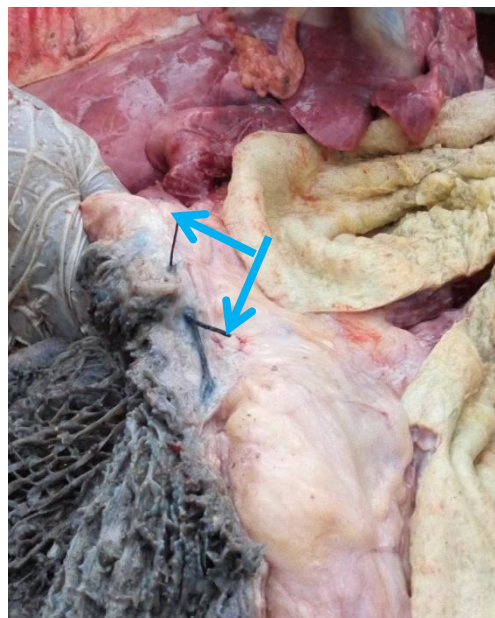


Fig. 6: Nails inside the reticulum (red arrows), Wire penetrating through reticular wall to pericardium (blue arrows).



Fig. 7: Various foreign bodies found in the reticulum (the wires in the petri-dish penetrated to pericardium)

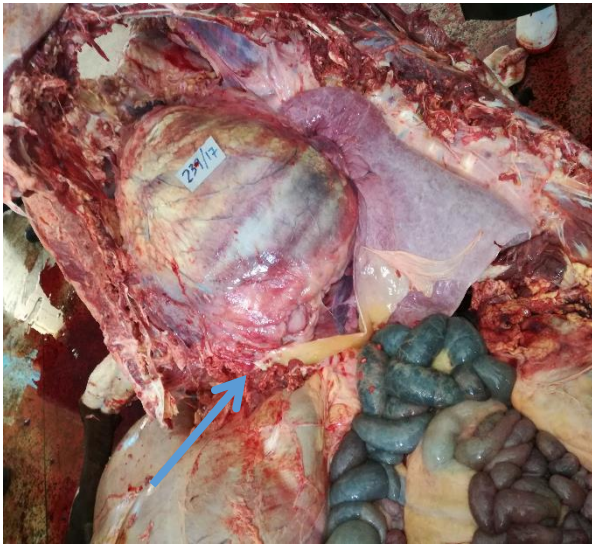

Fig. 7: Enlarged heart and fibrinous attachment (arrow).

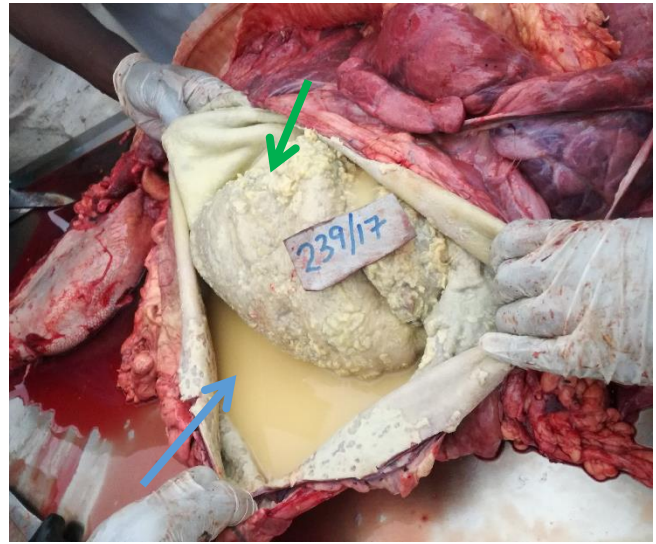

Fig. 8: A yellow purulent fluid accumulating in the pericardial sac (blue arrow), myocardium covered by fibrinous attachments resulting in a roughened surface (green arrow).

DISCUSSION

Traumatic reticulo-peritonitis and traumatic pericarditis are sporadic diseases of ruminants associated with ingestion of foreign materials, a common cause of abdominal surgeries in cattle. Pericarditis is inflammation of pericardium followed by collection of fibrinous or serous inflammatory contents due to penetration of foreign body through the reticular wall, diaphragm and pericardial sac (Grunder, 2002). Pericarditis is due to hematogenous spread of infectious conditions like pasteurellosis, salmonellosis, colibacillosis and anaerobic infections, thus, septicemia is observed (Grunder, 2002). Cattle are susceptible to foreign material than small ruminants since they use their lips for prehension and they rarely feed on chopped feeds (Braun, 2003). Moreover, honeycomb-like reticulum facilitate fixation of foreign material and contractility nature of reticulum pushes sharp foreign object through the wall (Mohamed, 2010; Malmo *et al.*, 2010), however, the severity of the sequelae to penetration of reticular wall depend on characteristic of foreign body (Radostits *et al.*, 2007). In most of the studies conducted, cattle with traumatic reticulitis reported

traumatic pericarditis, thus, most of the cattle with traumatic pericarditis may have traumatic reticulo peritonitis, since pericarditis is a complication of traumatic reticulo peritonitis (Mohamed, 2010). Reticulo peritonitis was however not observed in this because the penetrating wires penetrated cranial aspect of the reticulum to the pericardium.

The predisposition to hardware disease has an association with indiscriminate ingestion behavior of cattle, condition causing pica such as phosphorus deficiency (Divers and peek, 2008) and the anatomical location of organs, the diaphragm, pericardium and heart are located cranially to reticulum, liver position dorsally and medially, and spleen dorsally and laterally (Harwood, 2004). Sources of foreign bodies include; tyre wire since tyres are used to weigh down the silage and only removed when they start wearing out, this contributes to feed contamination (Cramer *et al.*, 2005), wide variety of metallic fragments at the construction sites, including fencing wires, copper wires, staples, nails, hypodermic needles and high tensile wire from palettes (Hateley, 2007; McCNamara and Baker, 2007). Mixer wagon blades disintegration act as major source of metallic

fragments (Daniel and Smith, 2008). The wires and nails found in the reticulum of the case in this study may be from decomposition wood from the animal houses and the sawdust (collected from carpentry workshops) that were used as bedding. The coins may be have coincidentally fallen into the animal feeds as the owners chopped the feeds.

Other risk factors include contraction of reticulum and pressure of calf during late pregnancy of effort of parturition promote penetration of the wall by foreign bodies (Shahin and Mohsen, 2010), this is similar to this case as the cow was 7 months pregnant. The prevalence of hardware disease increases with increase in the rate of exposure of cattle to foreign material and the nature of foreign bodies, stall fed animals with chopped feed, roughage and silage are at high risk of the disease, furthermore, female animals have increasing incidence of this disease than male animals due to the fact that female are kept for long periods than male (Radostitis *et al.*, 2007).

Clinical signs associated with traumatic reticulo-pericarditis includes distension of jugular veins, tachycardia, abnormal heart sounds, muffled heart sounds and edema of submandibular, brisket and ventral abdominal (Radostits *et al.*, 2007; Braun *et al.*, 2007, Abdelaal *et al.*, 2009;). The degree of jugular vein distension varies depending on cardiac tamponade (Jesty *et al.*, 2005; Braun *et al.*, 2007a). Tachycardia severity depend on compression of the heart by pericardial accumulation of fluids, however, in cows with idiopathic pericarditis, pericardiocentesis resulted in decreased heart rate (Jesty *et al.*, 2005). The heart rate was elevated in this case due to the large volume of pus (12 liters) that has accumulated in the pericardial sac. Muffled heart sounds are due to pericardial effusion and fibrinous changes in pericardium. Abnormal heart sound depends on etiology (Grunder, 2002), fibrinous changes, sounds heard includes rubbing, squeaking or scratching nature while predominance of fluid, splashing or gurgling sounds. The tamponade resulted in splashing heart sounds auscultated in this case. Cattle may stand with abducted elbow to facilitate heart functioning as well as alleviate pain, however the edema and jugular distension could be absent if pericardial fluid drains into reticulum through foreign body tracts (Grunder, 2002). The elbows were severely abducted in this case to facilitate the atrophied heart functioning as well as relief the pain that was evidenced by grunting and teeth grinding.

The general demeanor, condition and appetite of cattle is abnormal, sign of pain like bruxism and grunting, fever of 40.2°C, however, normal or sub-normal rectal temperature may be noted (Braun *et al.*, 2007). Elevated respiratory rate due to cardiac insufficiency or lung and ruminal motility direct involvement. Since pericarditis is associated with traumatic reticulo-peritonitis, test for foreign materials in reticular are positive in 85% of diseased animals (Braun *et al.*, 2007a). Careful carrying of the body gait and pronounced abducted elbows seen in Figure 2 in attempt to alleviate cardiac function, grunting and grinding of teeth was an intended expression of pain, this was similar findings reported by (Grunder, 2002; Orpin and Harwood, 2008). The respiratory rate and pulse rate were significantly higher than for a normal animal

similar finding reported by Mohamed, (2010). This condition should be distinguishing from simple indigestion, subclinical acute ruminal impaction and ketosis (Steen, 2007), however bloat may be the predisposing factor.

The diagnostic approach employed was based on cow-side test and laboratory tests (Cockcroft and Jackson, 2004). Cow-side test involved complete and clear history of the cow obtained from the farm, then a systematic examination of the case was employed.

Hematology result revealed leukocytosis, neutrophilia and lymphopenia an indication of underlying systemic infection due to normal flora from gastrointestinal system into systemic circulation similar findings reported by (Braun, 2009). Erythrocytopenia, lower hemoglobin concentrations and reduced packed cell volumes contrary to studies by Faisal and Shaimaa (2014) which showed cows with TRP have significance higher packed cell volume. Traumatic pericarditis results showed lymphopenia, basopenia, eosinopenia, monocytosis, neutrophilia, leucocytosis, erythrocytopenia, and low haemoglobin, however, haematological changes are significant in animals with traumatic pericarditis compared to animals with traumatic reticulopericarditis (Ghanem, 2010; Orpin and Harwood, 2008).

Post-mortem exam showed extensive fibrinous adhesions on reticulum, abdominal wall, pericardial wall, hydro-peritoneum, hydrothoracic, thickening cordinae tendinae and myocardial and collection of pus in pericardial sac these are similar finding reported by Ehsan *et al.* (2011). These case also recorded atrophied heart associated with sever pericarditis and extensive accumulation of liquefied pus. Inflammatory fibrinous change was extensively observed on surfaces of various organs and fibrin clots was observed in pus within pericardial sac similar to reports by Braun, (2009). However, the extend of the pathology depend on the nature of foreign materials, the extend of exposure to foreign materials and pregnancy stage, common at the last trimester, where the pressure due to developing fetus on the anterior organs exacerbates the condition which may lead to pronounce clinical picture and extensive pathological lesion, this was the situation in the case presented.

TRP management may involve either surgical or conservative treatment (Orpin and Harwood, 2012). Conservative therapy involves restriction of movement to prevent penetrating with from migrating cranially and allow magnet bolus to work, administration of non-steroidal anti-inflammatory drugs (NSAIDs) for analgesic effects, administration of broad-spectrum antibiotic treatment for at least five days and placement of magnet bolus in the rumen may aid in recovery (Braun *et al.*, 2003 and Orpin and Harwood, 2008). Surgical treatment being the gold standard in management of TRP may be done either immediate or delayed surgery. Immediate surgery less the risk of penetration of foreign objects in the cardiac region. Delayed surgery may be done carried out two days after onset of medical therapy in non-responsive cases (Orpin and Harwood, 2008).

Conclusions

This case report documents a case of mirco-cardia associated traumatic reticulo-pericarditis caused by

several wires penetrating through the diaphragm was earlier diagnosed with constipation and treated. However, the cow did not respond to the instituted treatment but showed other clinical sign, complete anorexic and brisket edema, the later sign lead to tentative diagnosis of traumatic reticulo-pericarditis. Thus, dairy animals showing signs of constipation, more than seven months' pregnancy and raised in urban and peri-urban areas, one should consider traumatic reticulo-pericarditis as differential diagnosis.

REFERENCES

- Abdelaal AM, M Floeck, Sli Maghawry and W Baumgartner, 2009. Clinical and ultrasonographic differences between cattle and buffaloes with various sequelae of traumatic reticuloperitonitis. *Vet Med*, 54: 399-406.
- Braun U, 2003. Ultrasonography in gastrointestinal disease in cattle. *Veterinary Journal*. 166: 112-124.
- Braun U, 2009. Traumatic pericarditis in cattle: clinical, radiographic and ultrasonographic findings. *Vet J*, 182: 176-86.
- Braun U, 2009a. Ultrasonography of the gastrointestinal tract in cattle. *Vet Clin North Amer Food Anim Prac*, 25: 567-90.
- Braun U, B Lejeune, G Schweizer, M Puorger and F Ehrensperger, 2007. Clinical findings in 28 cattle with traumatic pericarditis. *Vet Record*, 161: 558-563.
- Braun U, B Lejeune, G Schweizer, M Puorger and F Ehrensperger, 2007a. Clinical findings in 28 cattle with traumatic pericarditis. *Vet Record*, 161: 558-563.
- Braun U, S Warislohner, C Gerspach, S Ohlerth and K Nuss, 2018. Treatment of 503 cattle with traumatic reticuloperitonitis, *Acta Vet Scandinavica*, 60: 55.
- Cockcroft P and P Jackson, 2004. Clinical examination of the abdomen in adult cattle. In *Practice* 26: 304-317.
- Cramers T, KB Mikkelsen, P Andersen, C Enevoldsen and HE Jensen, 2005. New types of foreign bodies and the effect of magnets in traumatic reticulitis in cows. *Vet Record*, 157: 287-289.
- Daniel R and G Smith, 2008. Suspected bovine reticuloperitonitis associated with the metal components of a mixer wagon. *Vet Record*, 162: 563-564.
- Divers TJ and SP Peek, 2008. *Rebhun's disease of dairy cattle*. 2th Edition, Elsevier Inc, United States America, pp: 141-145.
- Ehsan T, DRM Mohamma, Dezfoli1, S Farhang, B Farshad, SH Majid and M Majid, 2011. Traumatic reticulopericarditis (TRP) in sheep: Report of 4 cases in a herd. *Slovenian Vet Reserve*, 48: 45-50.
- Faisal GH and NY Shaimaa, 2014. Advance techniques in traumatic reticuloperitonitis diagnosis: Colloge of Veterinary Medicine/ University of Baghdad. *AL-Qadisiya Vet Med Sci*, 13: 50-57.
- Ghanem Mohamed M, 2010. A comparative study on traumatic reticuloperitonitis and traumatic pericarditis in Egyptian cattle. *Turkey J Vet Anim Sci*, 34: 143-153.
- Gründer HD, 2002. Diseases of the Heart and Pericardium. In *Inner Medicine and Surgery of the Cattle*. 4th edition. Eds. G Dirksen, HD Gründer, M Stöber, Parey Buchverlag, Berlin, pp: 159-181.
- Harwood DG, 2004. Alimentary tract perforation in cattle caused by tyre wire. *Vet Record*, 154: 574-575.
- Hateley, 2007. Traumatic reticulo peritonitis in cows. *Vet Record*, 160: 882.
- Jesty SA, RW Sweeney, BA Dolente, and VB Reef, 2005. Idiopathic pericarditis and cardiac tamponade in two cows. *Amer Vet Med Assoc*, 226: 1555-1558.
- Malmo J, JJ Vermunt and TJ Parkinson, 2010. Diseases of the gastrointestinal tract. In: Parkinson TJ, Vermunt JJ, Malmo J (eds). *Diseases of Cattle in Australasia*. WB Vetlearn, Palmerston North, New Zealand, pp: 90-92.
- McNamara S. and I Baker, 2007. Traumatic reticulo peritonitis in cows. *Vet Record*, 160: 882-883.
- Orpin P and Harwood D, 2008. Clinical management of traumatic reticulo peritonitis in cattle. In *Practice*, 30: 544-51.
- Prasad VD, PR Kumar, NVV HariKrishna and D Bhagyaraju, 2017. Traumatic reticulitis, reticulo-peritonitis and pericarditis (Foreign body syndrome) in bovines. *Livestock Sci*, 8: 98-102.
- Radostits OM, CC Gay, KW Hinchcliff and PD Constable, 2007. *A Textbook of the Diseases of Cattle, Horses, Sheep, Pigs, and Goats*. 10th edition. Philadelphia, Saunders Elsevier.
- Shahin Hajighahramani and Mohsen Ghane, 2010. Traumatic Reticulo peritonitis in Cattle of Khorramabad. (center of Lorestan Provenience, West of Iran). *Global Vet*, 5: 135-139.
- Steen A, 2007. Field study on dairy cows with reduced appetite in early location: Clinical examination, blood and rumen fluid analyses. *Acta Vet Scandinavica*, 42: 219-28.